

# Extracorporeal shock wave therapy for the treatment of coccydynia: a series of 23 cases

Yousef Marwan<sup>1,2</sup> · Bashar Dahrab<sup>1</sup> · Ali Esmaeel<sup>1,3</sup> · Samir Abdulrazik Ibrahim<sup>1</sup> · Jassim Al-Failakawi<sup>1</sup>

Received: 14 November 2016 / Accepted: 23 December 2016  
© Springer-Verlag France 2017

## Abstract

**Background** Coccydynia can lead to significant functional disability and worsening of quality of life if not properly managed. In this study, we aim to assess the outcomes of extracorporeal shock wave therapy in patients with coccydynia.

**Methods** A prospective case series study was carried out from January to December 2015. Twenty-three patients, mean age of  $38.3 \pm 12.1$  (range 18–64), were included. The majority were females (13; 56.5%), had pain for at least 6 weeks (17; 73.9%) and had trauma to the sacro-coccygeal region (17; 73.9%). They had three sessions (one session per week for three consecutive weeks) of focused shock wave therapy directed to the maximal point of coccygeal tenderness. Numerical pain scale and Oswestry disability index were used to assess outcome.

**Results** Six (26.1%) patients did not complete the follow-up because of no, or minimal, improvement of their pain. After 6 months of follow-up, the median numerical pain scale significantly decreased from  $7.0 \pm 4.0$  to  $2.0 \pm 2.0$  among the 17 patients with coccydynia ( $p < 0.001$ ). The median Oswestry disability index improved from  $24.0 \pm 9.0$  before therapy to  $8.0 \pm 9.0$  at final follow-up ( $p < 0.001$ ). Before treatment, 12 (70.6%) patients had

moderate-to-severe disability. In contrast, no patients had severe disability and only one (5.9%) patient had moderate disability at final follow-up ( $p < 0.001$ ).

**Conclusion** Extracorporeal shock wave therapy had favorable outcomes in treating coccydynia. The majority of patients had partial relief of their pain and disability following this therapy.

**Keywords** Coccydynia · Coccygodynia · Coccyx · Pain · Extracorporeal shock wave therapy

## Introduction

Coccydynia, or coccygodynia, refers to pain in the region of the coccyx [1]. This condition can lead to chronic pain and functional impairment, limiting the quality of life of the patients. Patients usually complain of pain while sitting, which worsens when rising from a seated position and leaning back while seated [1]. Some patients also experience coccygeal pain with sexual intercourse or defecation, and females can have exacerbation during vaginal delivery or during the premenstrual period.

Coccydynia is a result of multiple factors. Trauma, in the form of direct fall, difficult vaginal delivery or repetitive minor injury due to sitting on hard objects, is by far the most common cause of coccygeal pain [2–4]. In addition, abnormal mobility of the coccyx and various morphologic features were found to be associated with coccydynia [2, 4–9]. For example, intercoccygeal subluxation, bony spicule, sharp ventral angulation of the coccyx and coccygeal retroversion are seen more frequently among patients with coccydynia compared to others. Other causes, such as degenerative disk disease, calcium deposition, tumors and infections, can lead to coccydynia [1, 10–12].

✉ Yousef Marwan  
yousefmarwan@hotmail.com

<sup>1</sup> Department of Orthopaedic Surgery, Al-Razi Orthopaedic Hospital, P.O. Box 24923, 13110 Safat, Kuwait City, Kuwait

<sup>2</sup> Division of Orthopaedic Surgery, McGill University Health Centre, McGill University, Montreal, QC, Canada

<sup>3</sup> Division of Orthopaedic Surgery, Department of Surgery, Faculty of Medicine, Health Sciences Center, Kuwait University, Kuwait City, Kuwait

Coccydynia usually responds well to non-operative treatment [1]. This includes nonsteroidal anti-inflammatory drugs, physical therapy in the form of pelvic floor training and postural training, ring-shaped cushions, local steroids injections and manual intra-rectal manipulation [13–16]. More favorable outcomes were seen with the combination of different treatment modalities, such as injections and manipulation [1, 17]. Epidural injections, radiofrequency ablation and ganglion impar blocks were also found to be helpful interventional procedures in the management of some cases of coccydynia [1, 13, 18–20]. For refractory cases, surgical intervention should be considered [3, 9, 21–24]. Coccygectomy, either partial or complete, can relieve the pain significantly in more than 90% of the patients [3, 9, 21, 22]. Few authors, in addition, have described the use of injecting polymethylmethacrylate cement for coccygeal fracture as coccygeoplasty, and others used vicryl suture as a tension band in a case of coccygeal instability [23, 24].

Recently, two groups of authors described the use of extracorporeal shock wave therapy (ESWT) for the treatment of coccydynia [25, 26]. In both reports, favorable results in terms of pain relief and functional improvement were achieved. Nevertheless, the causes and risk factors of coccydynia were limited in either study. We therefore aim to prospectively study the effect of ESWT for relieving the pain of coccydynia among patients with various predisposing factors. We also intend to assess the impact of this treatment in eliminating the functional disability associated with this condition. We hypothesize that ESWT is an effective treatment for relieving the pain and improving the functional capacity of patients with coccydynia.

## Methods

This is a prospective case series study that was conducted in our tertiary care center from January to December 2015. Ethical approval from our institutional review board (IRB) was obtained before patients' enrollment. In addition, the participants provided their written approval before being enrolled. It was clearly stated to the IRB and patients that the use of ESWT for coccydynia is investigational; it is not approved by the Food and Drug Administration (FDA) for this indication yet. The inclusion criteria were skeletal maturity, age of at least 18 years and both genders. Our inclusion was not limited to a single etiology of coccygeal pain; nevertheless, we included patients with different causes and features (e.g., acute vs. chronic, new onset vs. persistent) of coccydynia. Patients with psychiatric illness, pregnancy, recent pelvic or colorectal surgery, peri-anal conditions, lumbar spine disease, sacroiliac joint disease, local tumors or infection of the sacrococcygeal region, or

cauda equina tumors were excluded. In addition, patients with preexisting chronic pain conditions (e.g., fibromyalgia and polymyalgia rheumatica) were excluded.

Thirty-two patients with coccydynia presented to our center during the enrollment period (January to June 2015). The diagnosis was based on the presence of pain and tenderness localized to the coccygeal region on clinical assessment of the patients [1]. Out of the 32 patients, five declined to participate in the study, three were excluded because of lumbar spine disease, and one excluded for history of bipolar disease. Therefore, we ended up with 23 eligible patients (Table 1). Most of the included patients were females (13; 56.5%). Their mean age was  $38.3 \pm 12.1$  (range 18–64), and their mean body mass index (BMI) was  $28.2 \pm 3.8$  (range 22.3–36.6). Seventeen (73.9%) of the patients were complaining of coccydynia for at least 6 weeks before presentation. Direct trauma (i.e., fall or difficult vaginal delivery) was reported by 17 (73.9%) of the participants. All of them had coccygeal pain which exacerbates when being in a seated position and improved when minimizing the load on the coccyx by sitting on the legs (Table 2). Moreover, localized sacrococcygeal tenderness was observed in all of the patients. Other symptoms and signs of the patients can be found in Table 2.

Anteroposterior and lateral dynamic (standing and sitting) X-rays of the coccyx were obtained for all the patients after their presentation. Three (13.0%) patients had computed tomography (CT) scans done for them before being referred to our center. The radiologic assessment of coccydynia in our study included determining the type of coccyx, measuring the angle of mobility and looking for fractures and other morphologic finding (e.g., bony spicule, fusion ...etc.). The morphology of the coccyx was divided into six types based on the modified Postacchini and Massobrio classification [1, 5]. Moreover, the mobility of the coccyx was divided into normal (angle  $5^\circ$ – $25^\circ$ ), immobile/rigid ( $<5^\circ$ ) and hypermobile ( $>25^\circ$ ) [1, 2]. The angle of mobility was not measured in the presence of fracture or subluxation. Figures 1, 2, 3 and 4 represent examples of radiologic findings among our group of patients with coccydynia, while the findings of each individual patient can be found in Table 1. The majority of our patients had type II coccyx (12; 52.2%) and normal coccygeal mobility (8; 34.8%). Two (8.7%) patients had recent fractures of the coccyx, while three (13.0%) had old fractures. Additionally, fusion, subluxation and spicule were noted in six (26.1%), five (21.7%) and five (21.7%), respectively. Ventral angulation of the fifth sacral segment was seen in one (4.3%) of our patients.

Before starting the ESWT, the patients were asked to stop any treatment they use for coccydynia. They then had three sessions (one session per week for three consecutive weeks) of focused shock wave therapy delivering 3000

**Table 1** Characteristics, radiologic findings and treatment outcomes of patients with coccydynia treated by extracorporeal shock wave therapy (*n* = 23)

Pt	Age (years)	Sex	BMI (kg/m <sup>2</sup> )	Pain duration	Trauma	Radiologic findings			Follow-up duration	Pre-treatment		Final follow-up		Remarks	
						Type	Fracture	Mobility		Other	NPS	ODS	NPS		ODI
1	33	F	22.3	2 years; increased 2 months ago after VD	Difficult VD	II	No	Rigid	Spicule	6 months	2	28	1	20	None
2	45	M	23.8	3 months	None	II	No	Normal	Spicule	1 week	9	22	9	22	No improvement. Shifted to other treatment
3	26	M	32.9	15 years; increased in past 3 months	Fall from bicycle	II	Old; malunion	NA	None	1 month	6	20	5	18	Minimal improvement. Shifted to other treatment
4	61	F	27.4	3 years	None	III	No	Rigid	None	6 months	10	41	2	6	Pain increased the month before presentation
5	40	F	24.5	8 months	FFOH; Difficult VD	II	No	Normal	Fusion	6 months	8	28	2	10	None
6	40	M	27.4	4 months	Repeated minor trauma of riding horses	I	No	NA	Posterior subluxation	6 months	8	26	1	8	None
7	41	F	27.6	3 months	Difficult VD	II	No	NA	Posterior subluxation; Fusion, Spicule	6 months	7	36	4	16	None
8	18	M	24.3	3 days	None	II	No	Normal	None	6 months	7	22	0	0	Had similar pain 1 year back
9	18	M	28.9	4 weeks	None	I	No	Normal	None	6 months	4	18	1	4	None
10	49	M	31.4	1 week	FFOH	I	No	Hypermobile	None	6 months	8	26	2	4	None
11	48	F	25.0	14 years; increased in past 4 years	FFOH	III	No	Normal	None	1 week	9	38	9	38	No improvement. Shifted to other treatment
12	30	M	29.4	6 weeks	FFOH	V	No	Normal	None	6 months	5	20	2	10	None
13	64	F	28.4	1 month	FFOH	II	No	Rigid	Fusion	6 months	4	10	0	0	None
14	31	F	31.6	17 days	FFOH	II	Recent	NA	None	1 week	8	42	8	42	No improvement. Shifted to other treatment
15	30	F	23.4	1 year	FFOH	II	Old; nonunion	NA	None	6 months	6	22	3	14	None
16	36	F	36.6	8 years; increased 6 months ago after VD	FFOH	II	No	NA	Posterior subluxation; Fusion, Spicule	1 month	10	26	10	26	No improvement. Shifted to other treatment
17	52	M	28.3	2 months	FFOH 8 years ago treated. Now recurrence	II	Old; malunion	NA	None	9	24	4	12	12	None
18	42	M	26.0	1 year	None	V	No	Rigid	None	6 months	7	22	0	0	None
19	43	M	36.2	6 weeks	None	I	No	NA	Posterior subluxation	6 months	8	20	2	8	None

Table 1 continued

Pt	Age (years)	Sex	BMI (kg/m <sup>2</sup> )	Pain duration	Trauma	Radiologic findings			Follow-up duration	Pre-treatment		Final follow-up		Remarks	
						Type	Fracture	Mobility		Other	NPS	ODS	NPS		ODI
20	29	F	28.4	6 weeks	FFOH	I	Recent	NA	None	6 months	5	14	1	4	None
21	47	F	28.0	2 months	FFOH	III	No	Normal	Ventral angulation of S5	6 months	10	30	2	8	
22	26	F	30.8	2 years	FFOH	IV	No	NA	Anterior subluxation; Fusion; Spicule	6 months	10	44	3	22	None
23	32	F	25.4	3 weeks	FFOH	II	No	Normal	Fusion	1 week	7	16	7	16	No improvement. Shifted to other treatment

Pt patient, F female, M male, BMI body mass index, VD vaginal delivery, NA not applicable, S5 5th segment of the sacrum, NPS numeric pain scale, ODS Oswestry disability index

waves of 0.2 mJ/mm<sup>2</sup> directed to the maximal point of tenderness over the coccyx. This protocol of ESWT was used by Marwan et al. [25] for their two patients of coccydynia. During the ESWT sessions, the patients were lying in bed in a lateral position with both hips and knees flexed to the maximum possible degree in order to have good exposure to the sacrococcygeal region. All the patients tolerated the sessions very well.

The assessment of treatment outcomes was based on the numerical pain scale (NPS) and Oswestry disability index (ODI) [27, 28]. These were obtained from each patient before treatment, one week, four weeks, three months and six months following the three sessions of ESWT. Patients who did not improve initially and preferred to try other modalities of treatment were given the choice to do so.

Data were analyzed using the Statistical Package for Social Sciences version 17.0 (SPSS Inc, Chicago, Illinois, USA). Descriptive results in the form of frequencies, percentages, means, medians, standard deviations and interquartile ranges were calculated for the different variables. A *p* value of <0.05 was considered as the cutoff level of statistical significance. The association between two qualitative variables was assessed using Fisher's exact test, while that between a binary qualitative variable and a quantitative one was assessed using the Wilcoxon sign-rank test.

## Results

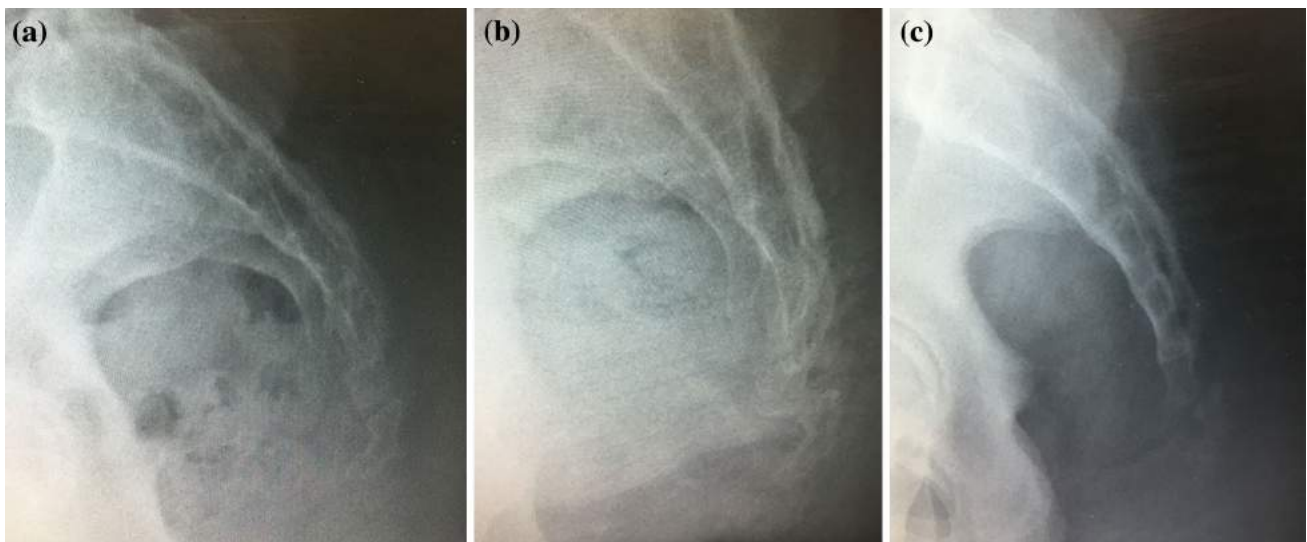
Out of the 23 patients, only six (26.1%) preferred not to complete the follow-up and try other treatments due to minimal or no improvement in their pain (Table 1). At final follow-up of six months, the median NPS significantly decreased (*p* < 0.001) from 7.0 ± 4.0 to 2.0 ± 2.0 among the 17 remaining patients with coccydynia (Table 3). In addition, the median ODI improved (*p* < 0.001) from 24.0 ± 9.0 before starting the ESWT to 8.0 ± 9.0 at final follow-up. Before treatment, 12 (70.6%) patients had moderate to severe ODI. In contrast, no patients had severe disability and only one (5.9%) patient had moderate disability at final follow-up (*p* < 0.001). No treatment-related complications were noted among any of the patients.

## Discussion

The preferred treatment of coccydynia is non-operative. Variable outcomes were reported in the literature [1]. Local pericoccygeal injections, with or without intra-rectal manipulation/massage, had a success rate between 60 and 85% [1, 17]. Similar rates were also observed in radiofrequency

**Table 2** Symptoms and signs of patients with coccydynia ( $n = 23$ )

Symptoms and signs	<i>N</i>	%
<b>Symptoms</b>		
Coccygeal pain	23	100.0
Radiation of pain to the lower back	7	30.4
Pain exacerbation with sitting position	23	100.0
Pain exacerbated when rising from a seated position	18	78.3
Pain with defecation	8	34.8
Pain with sexual activity (sexually active patients = 16)	5	31.3
Pain relief when sitting on legs	23	100.0
Pain relief when sitting on one buttock	22	95.7
History of difficult vaginal delivery (females had vaginal delivery = 8)	4	50.0
Premenstrual pain (pre-menopausal females = 11)	1	9.1
Trauma to the sacrococcygeal region	15	65.2
<b>Signs</b>		
Sacrococcygeal tenderness	23	100.0
Sacrococcygeal swelling	0	0.0
Sacrococcygeal mass	0	0.0
Peri-anal conditions	0	0.0

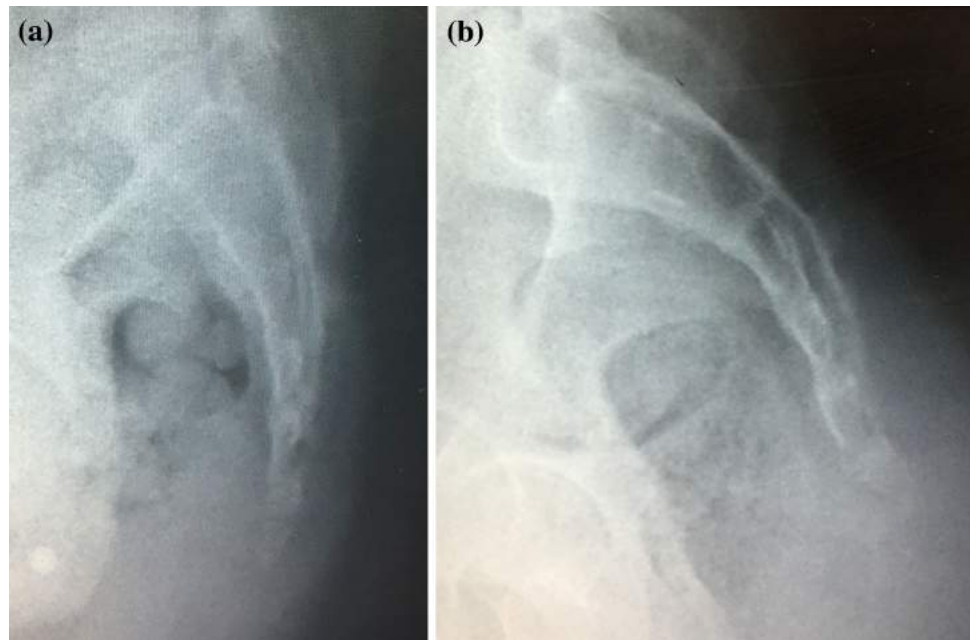
**Fig. 1** **a** Lateral standing X-ray of the coccyx of a 36-year-old female with coccydynia showing fusion between the coccygeal segments; **b** Lateral sitting X-ray of the same patient showing posteriorcoccygeal subluxation; **c** Lateral X-ray of the coccyx of a 43-year-old male with coccydynia showing posterior subluxation even in a standing view

ablation and ganglion impar blocks [18–20]. On the other hand, satisfactory results were reached in 77–92% of the patients following coccygectomy [1, 3, 9, 21, 22].

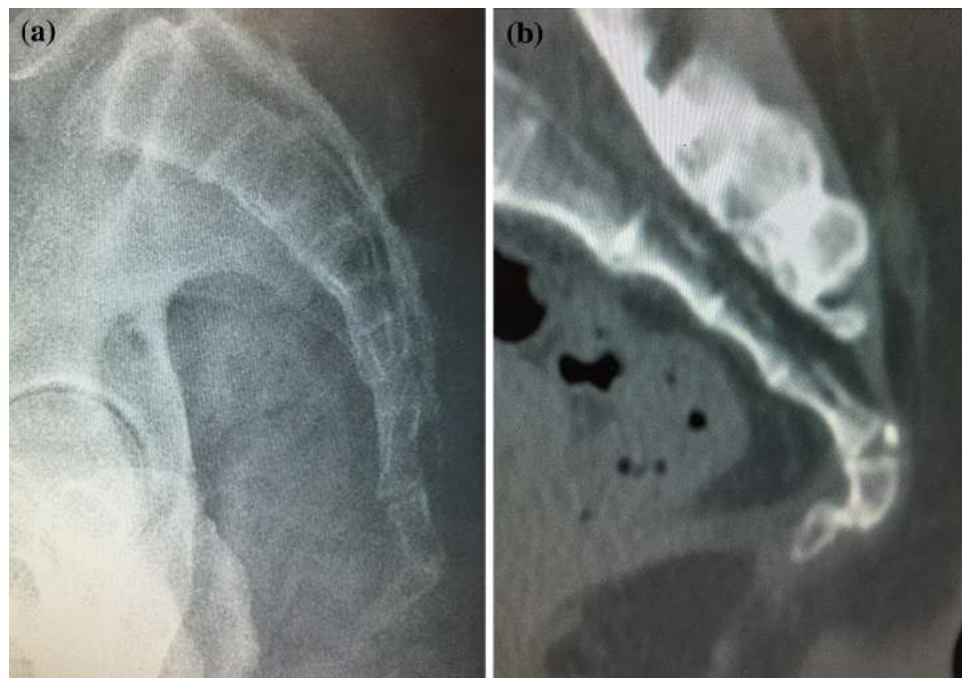
In this study, we demonstrate the effect of ESWT in the management of coccydynia among a group of patients with different etiologic/predisposing factors. We found that this therapy was effective in relieving the pain and disability of 74% of our patients. Nevertheless, this improvement was partial for the majority of the patients. Similar favorable outcomes of ESWT were also reported earlier in a report of two patients with coccydynia, of which one had coccygeal

retroversion and the other had subluxation [25]. One of these patients had complete relief of pain after a year of follow-up, while the other ended up with minimal persistent pain (1/10 on NPS). In a randomized controlled trial, researchers were also able to demonstrate superior results of shock wave therapy compared to physical therapy with combined interferential current and shortwave diathermy therapy [26]. They, however, used a different protocol for the delivery of shock waves than our study and did not report the details of the etiologic/risk factors of coccydynia among their patients.

**Fig. 2** **a** Lateral X-ray of the coccyx of a 18-year-old male showing type I coccyx (slightly curved pointing downward); **b** Lateral X-ray of the coccyx of a 30-year-old male showing type V coccyx (coccygeal retroversion)



**Fig. 3** **a** Lateral X-ray of the coccyx of a 26-year-old male showing old fracture malunion; **b** Sagittal view of a computed tomography scan of the coccyx of a 30-year-old female showing old fracture nonunion



The cause of coccydynia is usually multi-factorial [1]. Despite that, the pain is a result of an ongoing inflammatory effect in the coccyx and the surrounding soft tissues. This was the reason why ESWT was initially used for coccydynia [25]. The mechanical shock wave effect on the tissues is translated into a biological one by cell membrane hyperpolarization, Ras activation and production of oxygen radicals leading to local increase in growth factors such as vascular endothelial growth factor-A and transforming growth factor- $\beta$ 1 [29, 30]. This leads to neovascularization

and tissue healing and regeneration. We believe that this molecular effect of ESWT on the bone and soft tissue is the reason behind the positive results achieved in treating patients with coccydynia.

This study has some limitations. It is a case series study with no comparative group; thus, we cannot be sure if ESWT is better than other forms of treatment for coccydynia. A period of 6 months of conservative therapy might result in improvement of symptoms regardless of the use of shock wave therapy or a different method; thus, the

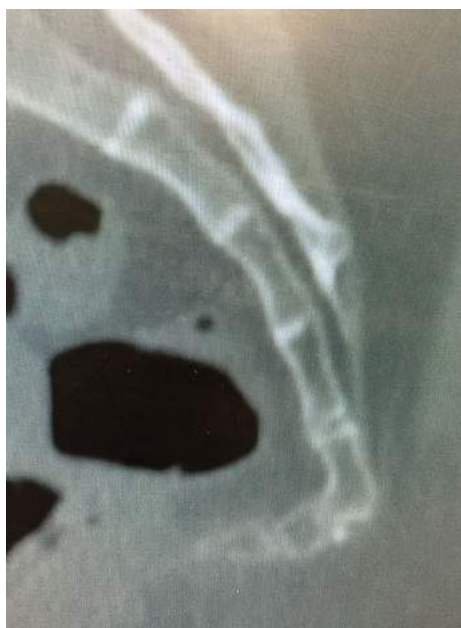**Table 3** Numeric pain scale and Oswestry disability index in patients with coccydynia before treatment and 6 months after extracorporeal shock wave therapy ( $n = 17$ )

Treatment outcomes	Outcomes		<i>p</i> value
	Before treatment	Final follow-up	
Numerical pain score (median $\pm$ IQR)	7.0 $\pm$ 4.0	2.0 $\pm$ 2.0	<0.001
Oswestry disability index (median $\pm$ IQR)	24.0 $\pm$ 9.0	8.0 $\pm$ 9.0	<0.001
Oswestry disability index ( <i>N</i> ; %)			<0.001
Minimal disability (0–20)	5 (29.4)	16 (94.1)	
Moderate disability (21–40)	10 (58.8)	1 (5.9)	
Severe disability (41–60)	2 (11.8)	0 (0.0)	
Crippled (61–80)	0 (0.0)	0 (0.0)	
Bed-bound or fake (80–100)	0 (0.0)	0 (0.0)	

Fisher's exact test for qualitative Oswestry disability index

Wilcoxon sign-rank test for numerical pain score and quantitative Oswestry disability index

IQR interquartile range

**Fig. 4** Sagittal view of a computed tomography scan of the coccyx of a 47-year-old female showing type III coccyx (angled forward sharply) and ventral angulation of the fifth sacral segment

availability of comparison groups would probably improve the impact of such study. Moreover, we are uncertain if the treatment effect will last for a long period following the therapy sessions since our follow-up was limited to six months. Our sample size was small also, and our patients had limited predisposing factors to coccygeal pain. Additionally, our group of patients was inhomogeneous; the study was not limited to a specific cause or feature of coccydynia. Therefore, we are not sure if ESWT can achieve favorable outcomes in all the different groups of patients with coccygeal pain.

Extracorporeal shock wave therapy was effective in relieving the pain and disability of coccydynia among our

group of patients. Future studies comparing this therapy with other methods of treating coccydynia are required. A comparison between different energy levels, or number of session, of shock waves could also demonstrate different results. Furthermore, studies assessing the combined effect of ESWT with other treatment options would be beneficial. We also recommend studying the effect of this treatment on specific causes of coccydynia (e.g., traumatic, abnormal mobility).

**Acknowledgement** We would like to thank the physiotherapy team of Al-Razi Orthopaedic hospital for their help throughout the study.

#### Compliance with ethical standards

**Conflict of interest** All authors declare no conflict of interest.

**Ethical standards** This research was given ethical approval from our institutional review board (IRB). The study complies with the current laws of our country.

## References

- Nathan ST, Fisher BE, Roberts CS (2010) Coccydynia: a review of pathoanatomy, aetiology, treatment and outcome. *J Bone Joint Surg Br* 92(12):1622–1627
- Maigne JY, Guedj S, Straus C (1994) Idiopathic coccygodynia: lateral roentgenograms in the sitting position and coccygeal discography. *Spine* 19(8):930–934
- Pennekamp PH, Kraft CN, Stütz A, Wallny T, Schmitt O, Die-drich O (2005) Coccygectomy for coccygodynia: does patho-genesis matter? *J Trauma* 59(6):1414–1419
- Maigne JY, Pigeau I, Aguer N, Doursounian L, Chatellier G (2011) Chronic coccydynia in adolescents. A series of 53 patients. *Eur J Phys Rehabil Med* 47(2):245–251
- Postacchini F, Massobrio M, Idiopathic coccygodynia (1983) Analysis of fifty-one operative cases and a radiographic study of the normal coccyx. *J Bone Joint Surg Am* 65(8):1116–1124
- Maigne JY, Doursounian L, Chatellier G (2000) Causes and mechanisms of common coccydynia: role of body mass index and coccygeal trauma. *Spine (Phila Pa 1976)* 25(23):3072–3079

7. Woon JT, Maigne JY, Perumal V, Stringer MD (2013) Magnetic resonance imaging morphology and morphometry of the coccyx in coccydynia. *Spine (Phila Pa 1976)* 38(23):E1437–E1445
8. Marwan YA, Al-Saeed OM, Esmaeel AA, Kombar OR, Bendary AM, Azeem ME (2014) Computed tomography-based morphologic and morphometric features of the coccyx among Arab adults. *Spine (Phila Pa 1976)* 39(20):E1210–E1219
9. Doursounian L, Maigne JY, Jacquot F (2015) Coccygectomy for coccygeal spicule: a study of 33 cases. *Eur Spine J* 24(5):1102–1108
10. Richette P, Maigne JY, Bardin T (2008) Coccydynia related to calcium crystal deposition. *Spine (Phila Pa 1976)* 33(17):E620–E623
11. Kim HS, Yang SH, Park HJ, Park HB, Cho HS (2013) Glomus tumor as a cause of coccydynia. *Skeletal Radiol* 42(10):1471–1473
12. Gavriilidis P, Kyriakou D (2013) Sacrococcygeal chordoma, a rare cause of coccygodynia. *Am J Case Rep* 14:548–550
13. Hodges SD, Eck JC, Humphreys SC (2004) A treatment and outcomes analysis of patients with coccydynia. *Spine J* 4(2):138–140
14. Maigne JY, Chatellier G, Faou ML, Archambeau M (2006) The treatment of chronic coccydynia with intrarectal manipulation: a randomized controlled study. *Spine (Phila Pa 1976)* 31(18):E621–E627
15. Mitra R, Cheung L, Perry P (2007) Efficacy of fluoroscopically guided steroid injections in the management of coccydynia. *Pain Physician* 10(6):775–778
16. Howard PD, Dolan AN, Falco AN, Holland BM, Wilkinson CF, Zink AM (2013) A comparison of conservative interventions and their effectiveness for coccydynia: a systematic review. *J Man Manip Ther* 21(4):213–219
17. Ramsey ML, Toohey JS, Neidre A, Stromberg LJ, Roberts DA (2003) Coccygodynia: treatment. *Orthopedics* 26(4):403–405
18. Datir A, Connell D (2010) CT-guided injection for ganglion impar blockade: a radiological approach to the management of coccydynia. *Clin Radiol* 65(1):21–25
19. Gopal H, Mc Crory C (2014) Coccygodynia treated by pulsed radio frequency treatment to the Ganglion of Impar: a case series. *J Back Musculoskelet Rehabil* 27(3):349–354
20. Gunduz OH, Sencan S, Kenis-Coskun O (2015) Pain relief due to transsacrococcygeal Ganglion Impar block in chronic coccygodynia: a pilot study. *Pain Med* 16(7):1278–1281
21. Trollegaard AM, Aarby NS, Hellberg S (2010) Coccygectomy: an effective treatment option for chronic coccydynia: retrospective results in 41 consecutive patients. *J Bone Joint Surg Br* 92(2):242–245
22. Karadimas EJ, Trypsiannis G, Giannoudis PV (2011) Surgical treatment of coccygodynia: an analytic review of the literature. *Eur Spine J* 20(5):698–705
23. Bergkamp AB, Verhaar JA (1995) Dislocation of the coccyx: a case report. *J Bone Joint Surg Br* 77(5):831–832
24. Dean LM, Syed MI, Jan SA, Patel NA, Shaikh A, Morar K, Shah O (2006) Coccygeoplasty: treatment for fractures of the coccyx. *J Vasc Interv Radiol* 17(5):909–912
25. Marwan Y, Husain W, Alhajji W, Mogawer M (2014) Extracorporeal shock wave therapy relieved pain in patients with coccydynia: a report of two cases. *Spine J* 14(1):e1–e4
26. Lin SF, Chen YJ, Tu HP, Lee CL, Hsieh CL, Wu WL, Chen CH (2015) The effects of extracorporeal shock wave therapy in patients with coccydynia: a randomized controlled trial. *PLoS One* 10(11):e0142475
27. Mannion AF, Balagué F, Pellisé F, Cedraschi C (2007) Pain measurement in patients with low back pain. *Nat Clin Pract Rheumatol* 3(11):610–618
28. Fairbank JC, Pynsent PB (2000) The Oswestry disability index. *Spine (Phila Pa 1976)* 25(22):2940–2952
29. Wang CJ, Wang FS, Yang KD, Weng LH, Hsu CC, Huang CS, Yang LC (2003) Shock wave therapy induces neovascularization at the tendon-bone junction. A study in rabbits. *J Orthop Res* 21(6):984–989
30. Zelle BA, Gollwitzer H, Zlowodzki M, Bühren V (2010) Extracorporeal shock wave therapy: current evidence. *J Orthop Trauma* 24(Suppl 1):S66–S70